

Ultrasound and fistula catheter: a strategy to reduce vascular access injuries

Laia Reixach-Aumatell, Hilda Fernández-Punset, Isabel Pérez-García, Alicia Rey-Miguel

Nephrology Service, Fundació Salut Empordà, Figueres, Spain

Please cite this article in press as:

Reixach-Aumatell L, Fernández-Punset H, Pérez-García I, Rey-Miguel A. Ultrasound and fistula catheter: a strategy to reduce vascular access injuries. *Enferm Nefrol.* 2025;28(1):55-58

Corresponding author:

Laia Reixach Aumatell
lreixach2@salutemporda.cat

Reception: 11-25-24
Acceptance: 02-15-25
Publication: 03-30-25

ABSTRACT

The use of ultrasound has been shown to improve knowledge of vascular access, facilitating the choice of puncture sites and increasing confidence in difficult punctures. With the aging of the hemodialysis population, vascular deterioration complicates access to the native arteriovenous fistula, thus increasing the risk of complications such as hematomas, thrombosis, and stenosis. These difficulties can lead to the use of central venous catheters, increasing morbidity and mortality.

Conventional metal needles can damage the native arteriovenous fistula, reducing its longevity. As an alternative, the fistula catheter minimizes vascular damage by reducing the risk of extravasations and hematomas. This study compared both types of needles in 12 patients for 8 months (2 were excluded due to death, leaving 10 patients that were categorized into 2 groups). Ultrasounds were performed to evaluate vascular involvement.

Results showed that 80% of patients with conventional metal needles presented injuries, while only 40% of the fistula catheter group developed damage, which resolved during the study. No significant changes in native arteriovenous fistula flow were observed in either group.

Ultrasound monitoring allowed changes to puncture sites to prevent long-term complications. It is concluded that the use of fistula catheters, along with ultrasound and trained personnel, can reduce complications and prolong the life of vascular access, avoiding unnecessary surgical procedures and improving the quality of hemodialysis treatment.

RESUMEN

Ecografía y catéter fístula: una estrategia para reducir lesiones en el acceso vascular

El uso de ecografía ha demostrado mejorar el conocimiento del acceso vascular, facilitando la elección de zonas de punción y aumentando la confianza en punciones dificultosas. Con el envejecimiento de la población en hemodiálisis, el deterioro vascular complica el acceso a la fístula arteriovenosa nativa, incrementando el riesgo de complicaciones como hematomas, trombosis y estenosis. Estas dificultades pueden llevar al uso de catéteres venosos centrales, aumentando la morbimortalidad.

Las agujas metálicas convencionales pueden causar daño en la fístula arteriovenosa nativa, reduciendo su longevidad. Como alternativa, el catéter fístula minimiza el daño vascular al reducir el riesgo de extravasaciones y hematomas. Este estudio comparó ambos tipos de agujas en 12 pacientes durante 8 meses. Se excluyeron 2 por defunción, dejando 10 pacientes divididos en dos grupos. Se realizaron ecografías para evaluar la afectación vascular.

Los resultados mostraron que el 80% de los pacientes con aguja metálica convencional presentaron lesiones, mientras que solo el 40% de los del grupo catéter fístula desarrollaron daños, los cuales se resolvieron durante el estudio. No se observaron cambios significativos en el flujo de la fístula arteriovenosa nativa en ninguno de los grupos.

El control ecográfico permitió modificar zonas de punción para prevenir complicaciones a largo plazo. Se concluye que el uso de catéter fístula, junto con la ecografía y personal capacitado, puede reducir complicaciones y prolongar la vida del

acceso vascular, evitando intervenciones quirúrgicas innecesarias y mejorando la calidad del tratamiento en hemodiálisis.

To the Editor

We would like to contribute our knowledge and experience with the use of ultrasound, as well as with catheter fistula (CF) needles as an alternative to conventional metal needles. According to our experience, by switching to these needles and thanks to ultrasound guidance by nursing staff, we have been able to avoid or prevent possible complications, reducing the injuries caused by cannulation.

It has been studied that the use of ultrasound by nurses improves knowledge of the vascular access (VA), assists in the selection of cannulation sites, and increases nursing confidence in new or difficult VAs¹.

In recent years, the profile of patients starting renal replacement therapy (RRT) on hemodialysis (HD) has changed, with a significant increase observed in patients over 75 years of age. These patients have increased age and morbidity, which can complicate access to a native arteriovenous fistula (nAVF) due, among other factors, to age-related vascular deterioration².

As a result, cannulation can be more complex, increasing the risk of complications such as infiltrations, hematomas, repeated punctures, stenosis, thrombosis, and aneurysms. This not only causes discomfort for the patient but also increases the workload of healthcare personnel. In some cases, these difficulties may necessitate the placement of a central venous catheter (CVC), which carries a higher risk of morbidity and mortality².

The repeated use of conventional metal needles in HD can cause vascular damage to the nAVF. This damage can be a key factor affecting VA longevity. Moreover, arm movement or flexion during dialysis may contribute to this damage^{3,4}.

The alternative to conventional metal needles is the CF needle, which consists of a biocompatible cannulation device made of an internal metal needle and an external plastic fluoropolymer catheter. The latter remains inside the vessel during treatment. The plastic cannula minimizes damage to the vessel wall, risk of extravasation, and the development of hematomas³.

Using ultrasound to monitor the VA in dialysis units allows for individualized

cannulation, which may lead to improved outcomes and greater VA longevity⁵.

In recent years, nurses have been trained in the use of vascular ultrasound as a work tool, helping to improve knowledge of the VA, selecting cannulation sites, and increasing confidence when accessing new or difficult VAs.

Currently, in our center we use both types of needles, selecting the material based on the unit's internal cannulation guide: "Guide for Selecting Cannulation Material for nAVF/pAVF" (figure 1).

In this study, we compared conventional metal needles versus CF needles over a period of 8 months, in different patients with similar anatomical conditions, to determine

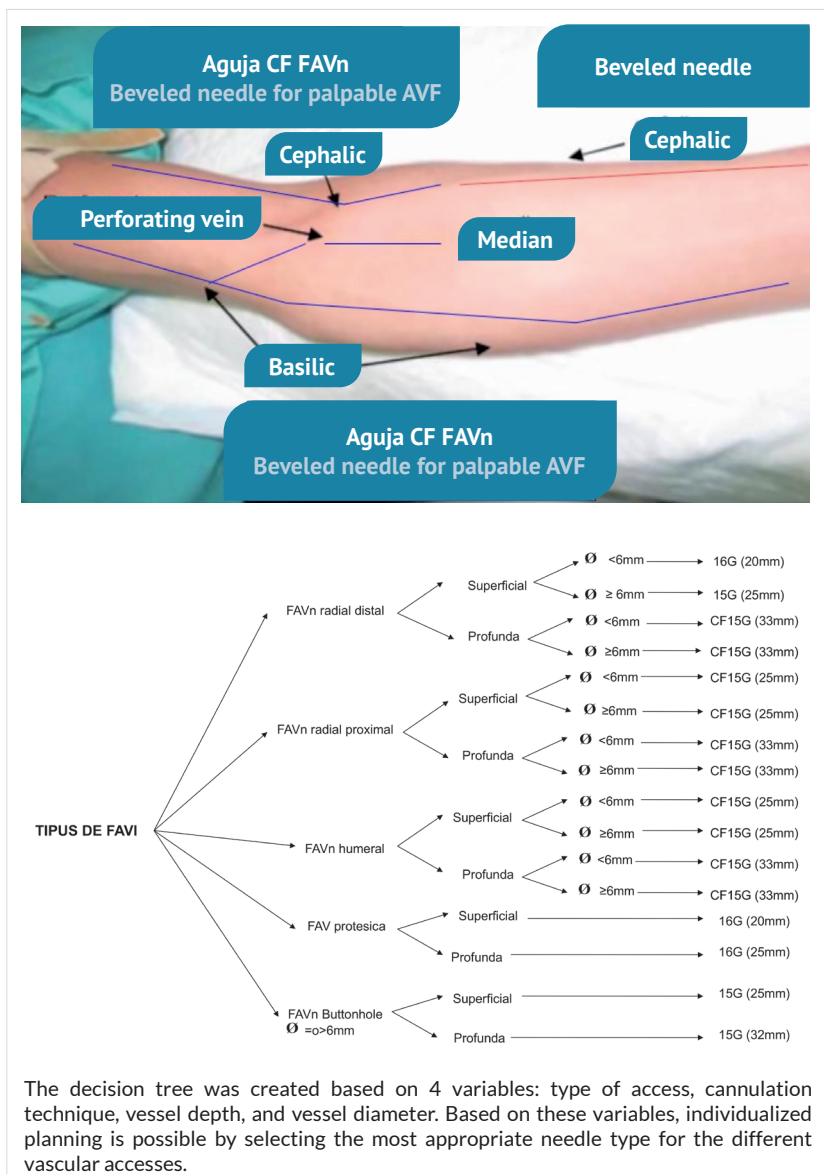


Figure 1. Guide for the selection of puncture material for AVF n/p.

which material is more optimal for minimizing vascular wall damage. To do this, nurses performed ultrasound monitoring, observing the appearance of vascular wall injuries as well as fistula function.

Our objective was to assess, via ultrasound, the impact on the posterior wall of the nAVF related to the choice of cannulation material (metal needle vs. CF needle).

We included a total of 12 patients with radiocephalic nAVFs, with arterial and venous cannulation segments of at least 4 cm, using a rope-ladder technique. Patients were randomly divided into two groups: 6 with conventional metal needles and 6 with CF needles. Two were excluded due to death. The study was completed by 10 patients –5 with metal needles and 5 with CF needles.

Each of the 10 patients underwent a baseline ultrasound, confirming no preexisting lesions in the cannulation areas. At the end of the study, a morphological and functional Doppler ultrasound was performed.

During the study, a session log sheet was completed detailing any cannulation issues, hematoma appearance, etc.

Each month, an ultrasound was performed to assess whether any new lesions had appeared in the nAVF vessel, and findings were recorded.

At the end of the study period, among the 5 patients with conventional metal needles, 4 presented with lesions (80%): 3 in the posterior wall and 1 in the anterior wall.

The latter was due to a cannulation problem that caused a superficial hematoma. Lesions appeared during the first, fourth, and fifth months and persisted until the end of the study.

Among the 5 patients with CF needles, 2 presented with lesions (40%), both in the posterior wall. These appeared in on months 2 and 5 and resolved during the course of the study.

There were no significant changes in nAVF flow measurements before and after the study in either group.

CF needles caused fewer vascular wall injuries compared to conventional metal needles.

Vessel wall injuries occurred mostly in the posterior wall, and those in the CF group resolved by the end of the study. In contrast, the injuries caused by metal needles persisted.

Monthly ultrasound monitoring of the nAVF allowed us to change cannulation sites when posterior wall injuries were detected, helping to avoid long-term problems such as stenosis, which is the main issue leading to nAVF dysfunction. All these tools could help prolong the life of nAVFs, avoiding surgical interventions like angioplasty, superficialization of the nAVF, and placement of CVCs in cases of nAVF dysfunction.

In this study, nurses were responsible for monitoring and recording patients' VAs, detecting injuries or dysfunctions early through physical and ultrasound examination. This enhances nursing empowerment, allowing them to anticipate complications and improve VA survival.

Based on our results, we can observe that having access to a variety of cannulation needles –especially CF needles– as well as having a specific guide for choosing materials for nAVFs and prosthetic AVFs (pAVFs), using proper cannulation techniques, having an ultrasound device, and having trained professionals can all support individualized cannulation. This individualization may help reduce the number of complications, such as extravasation or infiltration of the vascular access wall during cannulation. However, it is important to note that while these factors appear to have a positive impact, further studies are needed to confirm and quantify their effect on complication reduction.

Vascular damage associated with needle use in HD is a significant concern. The implementation of appropriate techniques and continuous monitoring are essential to preserve VA function and ensure effective treatment.

Conflicts of interest

The authors declare no conflicts of interest related to the research, authorship, and/or publication of this manuscript.

Funding

The authors declare that no external funding was received.

REFERENCES

1. Ibeas J, Roca-Tey R. Monitorización y vigilancia del acceso vascular. En: Guía española de acceso vascular para Hemodiálisis. Grupo Español Multidisciplinar de Acceso Vascular (GEMAV). *Enferm Nefrol*. 2018 [cited 1 Mar 2025];21(Supl 1):S63-88. Available from: https://www.seden.org/files/documents/Elementos_1301_guia-seden-linkada18-09-34.pdf
2. Cano M, López Castillo N. Punción de fístulas arteriovenosas en hemodiálisis: técnica convencional y punción ecoguiada. *Rev Enferm Docente*. [Internet]. 2023 [cited 28 Oct 2024];118:13-6. Available from: <https://www.sspa.juntadeandalucia.es/servicioandaluzdesalud/hospital/virgen-victoria/sites/default/files/2024-09/118-03-ES-Punci%C3%B3n%20de%20f%C3%ADstulas%20arteriovenosas%20en%20hemodi%C3%A1lisis.pdf>
3. Martínez Ocaña O, Rodríguez Estaire J, Ruiz Sanz B, Martín Navarro JA, Mérida Herrero E. Catéter-fístula: una nueva alternativa en la punción de accesos vasculares. *Rev Soc Esp Enferm Nefrol* [Internet]. 2010 [cited 28 Oct 2024];13(2):105-11. Available from: <http://>

scielo.isciii.es/scielo.php?script=sci_arttext&pid=S1139-13752010000200003&lng=es

4. Mallo Domínguez A, Carratalá Chacón J, Folch Morro MJ, Renau Ortells E, Cerrillo García V, Aicart Saura C, Bort Castelló J, Salvador Lengua C. Estudio comparativo de dos tipos de agujas para hemodiálisis: aguja clásica vs catéter Supercath. *Enferm Nefrol.* 2009;12(3):114-8.
5. Moyano Franco MJ, Salgueira Lazo M, Roca-Tey R. Punción ecoguiada del acceso vascular para hemodiálisis. En: Lorenzo V, López Gómez JM, editores. *Nefrología al día* [Internet]. 2024 [cited 4 Jan 2025]. Available from: <https://nefrologiaaldia.org/es-articulo-puncion-ecoguiada-del-acceso-vascular-para-hemodialisis-592>



This is an open access article distributed under a Creative Commons licence.
<https://creativecommons.org/licenses/by-nc/4.0/>